

## Herpes Zoster As An Immune Reconstitution Disease in A HIV Positive Patient

Jayanti Humbe<sup>1</sup>, Mandakini Mandale<sup>2</sup>, Ruchika Agrawal<sup>3</sup>

<sup>1</sup>(Department of Oral Pathology, Government Dental College & Hospital, Aurangabad, Maharashtra, India)

<sup>2</sup>(Department of Oral Pathology, Government Dental College & Hospital, Aurangabad, Maharashtra, India)

<sup>3</sup>(Department of Oral Pathology, Government Dental College & Hospital, Aurangabad, Maharashtra, India)

**Abstract :** AIDS has been known since eras for its deadly nature. Human Immunodeficiency Virus (HIV) is a virus that attacks the human immune system. CD4 cells or T-helper cells are a type of white blood cell that fight infection and their count indicates the stage of HIV or AIDS in a patient. Clinical symptoms are also seen in the oral cavity. Antiretroviral therapy are the medications that treat HIV. They slow down the virus. The goal of ARV therapy in case of individuals with compromised immunity is to strengthen back the immunity. However, abnormal effects that may complicate the existing situation occurs. After initiation of ART, patient may develop various infections like bacterial, viral and fungal infections within 90 days. This type of infection is known as Immune Reconstitution disease (IRD). This should be differentiated from clinical symptoms due to failure of the ART. Various infections that manifest in the oral cavity could help to diagnose this disease and thus prevent the complications due to this disease. A case of herpes zoster developed in a HIV positive patient 10 days after initiation of ART is reported here along with its pathogenetic and diagnostic perspective.

**Keywords:** Herpes Zoster, Human Immunodeficiency Virus, CD4, Immune Reconstitution Disease

### I. Introduction

Herpes zoster (HZ) is caused due to reactivation of latent varicella zoster virus (VZV) infection in cranial nerve or dorsal root ganglia. The virus spread along the sensory nerve to the dermatome. It had been most frequently seen in the elderly and among immunosuppressed patients.<sup>[1]</sup> The incidence of HZ is around 0.15–0.33/100 person - years in the general population, with a higher incidence (0.5–0.9/100 person-years) in individuals aged 50–80 years.<sup>[2]</sup>

HIV infection is a risk factor for the development of HZ and its complications. It's incidence in HIV infected individuals ranges from 2.9–5.1/100 person every year.<sup>[2]</sup> It may be 1st indication of HIV infection.<sup>[3]</sup> According to Abdalla et al (2014), out of 40 patients of HZ screened, 6 were seropositive.<sup>[4]</sup> In a subset of HIV infected patients, HZ has been observed to occur after initiation of Highly Active Antiretroviral therapy (HAART). This could be dysregulated immune response after initiation of HAART wherein there is recovery of CD4 +T cell number without regaining their normal function. This is an immune reconstitution disease (IRD).<sup>[5]</sup>

In IRD, there is appearance of a new infection/disease process soon after initiation of therapy. Infections associated with IRD are mycobacteria, fungal, viral, protozoal and bacterial. Autoimmune diseases, inflammatory conditions and malignancies are also associated with IRD.<sup>[5,6]</sup> Pere doming et al, reported 8% patients with HZ after initiating HAART.<sup>[7]</sup> Herewith reported is a case of a 32 year old male HIV infected patient who developed HZ after initiation of HAART.

### II. Case Report

A 32 year old male, reported to the hospital with a chief complaint of eruptions on right side of face since 2 days and white coating on tongue since 4 days.

Extraoral Examination showed multiple vesicular eruptions seen unilaterally on lower lip involving entire right cheek and right ear. Periorbital oedema was noted with right eye. Crustation was seen on eruption. (Fig 1 A, B, C). Physical examination showed no other remarkable findings.

Intraoral Examination revealed white coating and erosive areas on tongue extending from tip to anterior faucial pillars and from midline to the lateral border of tongue involving ventral surface and floor of mouth. Unilateral palatal erythema was also noted. (Fig. 2 A, B)

Past Medical History revealed AIDS since 6 years. CD4 count was normal and thus he was not started with antiretroviral therapy. There was decrease in CD4 count and initiation of HAART, consisting of Lamivudine, Efavirenz, Tenofovir, Fumarate 10 days before appearance of above symptoms. CD 4 count was 312 cells /cubic mm. CD4 lymphocyte percentage was 18%. Normal CD 4 count is 500-1500 cells per cubic millimeter. Normal reference range for CD4 lymphocyte being 31% to 60%.

Vesicular fluid was collected from base of the eruption and smear was prepared. It showed inflated cells with smooth external contour present in groups. Based on clinical and cytological examination, a diagnosis of Herpes Zoster as an immune reconstitution disease was given. ( Fig.3 A)

While maintaining HAART, the patient was treated with Acyclovir 20mg/kg orally 4 times a day for 10 days to suppress replication of the provoking pathogen and to reduce antigen load. Follow up after 15 days was done. It was seen that the lesion disappeared and CD4 count raised to 418 cells/ cubic mm. (Fig. 4. A, B)

### **III. Discussion**

Immune reconstitution is defined as a CD4+ count of  $>200$  cells  $\text{mm}^{-3}$  and an increase of  $\geq 100$  cells over baseline any time since starting HAART (Arici et al,2001). According to IRD definitions proposed by different investigators, it is basically an unmasking<sup>7</sup> or paradoxical worsening of a preexisting infection following the initiation of HAART, in the presence of improved immune response and a decreasing viral load. Features are consistent with an inflammatory process.<sup>[8]</sup>

The pathogenesis of IRD is multifactorial. It depends on pre-existing microbial burden and the degree of virulence of the pathogen involved. It also depends on characteristics of the particular immune response to the initiating pathogen, i.e. whether it will be an excessive or a normal immunoinflammatory response. After the initiation of HAART, HIV-IRD occurs in relation to a host immune restoration. It is supplemented by elevation of CD4+T cell counts and a decrease in plasma HIV load. It has been found that most cases of IRD in HIV-seropositive subjects occur within the first 12 weeks after the initiation of HAART, before the reconstitution of the immune system has reached its full potential. During this period there is no production of new naïve CD4+T cells by the thymus. The functional capacity of the CD4+T cells and CD8+ cytotoxic T cells is not yet restored to its full capacity. However, there is gradual immune reconstitution. There is a progressive improvement in the function of antigen presenting cells, a shift in the cytokine profile toward a Th-1 protective type, and a redistribution of CD4+ memory cells from the lymph nodes to the circulation.<sup>[9]</sup> This may also be explained as, following ART, there is suppression of HIV replication. This leads to variable reversal of HIV induced immune defects e.g. CD4 T cell depletion, depletion or dysfunction of antigen presenting cells. This causes an imbalanced effector and regulatory cellular immune responses against pathogen specific antigens, thus causing immunopathology resulting in atypical presentation of opportunistic infection.<sup>[6]</sup> Thus there is more of qualitative defect of immune cells.

There is a proposed criteria for diagnosis of immune reconstitution Disease in HIV patients on antiretroviral therapy (French et al, 2004). A diagnosis requires both major criteria, or 1 Major criteria and 2 Minor criteria.

Major Criteria

**A. Atypical presentation of opportunistic infections or tumors in patients responding to ART, manifested by any of the following:**

**1. Localized disease. 2. Exaggerated inflammatory reaction. 3. Atypical inflammatory response in affected tissues. 4. Progression of organ dysfunction or enlargement of preexisting lesions**

**B. Decrease in plasma HIV RNA level  $>1$  log<sub>10</sub> copies/ml.**

**1. Increase in CD4 count after ART.**

**2. Increase in an immune response specific to the relevant pathogen**

**3. Spontaneous resolution of disease after continuation of ART.<sup>[8]</sup>**

According to results of one study, patients with CD4+ counts between 50 and 200 cells/mm<sup>3</sup> and on HAART appeared to be at the highest risk for a herpes zoster.

Herpes zoster is caused by reactivation of latent VZV in cranial-nerve or dorsal-root ganglia. The rash of herpes zoster is dermatomal. It does not cross the midline. This is a feature that is consistent with reactivation from a single dorsal-root or cranial-nerve ganglion. The rash is often preceded by tingling, itching, or pain for 2 to 3 days. It begins as macules and papules, which evolve into vesicles and then pustules. The rash usually dries with crusting in 7 to 10 days. In the present case, similar findings were seen thus finalizing the diagnosis of Herpes Zoster.

In the present case, Major Criteria was Localized disease and the Minor Criteria were - 1. Increase in CD 4 count after ART . 2. Spontaneous Resolution of disease after continuation of ART. The patient presented with herpes zoster as a manifestation of IRD after 10 days of HAART. The CD4+ count increased from 312 to 418 cells/mm<sup>3</sup>, and the HIV viral load decreased. This can be considered as unmasking IRD not paradoxical IRD. Unmasking IRD is defined as a clinical event in which opportunistic disease, which was not present at the time of initiation of ART, becomes clinically manifest as a result of HAART-induced immune recovery. Whereas, paradoxical IRD is used to denote IRD among patients who are already receiving medication for an opportunistic disease, and in whom immune recovery after initiation of HAART provokes the clinical deterioration of that disease during the initial treatment. The unilateral whitish scrapable patch may be

an atypical presentation of the condition.<sup>[10]</sup> Other causes, including drug resistance or toxicity, drug malabsorption, non-adherence to regimen, delayed recovery of immune function after initiation of HAART, and superinfection by other pathogens were excluded. Therefore, the diagnosis of IRD is done. Findings of some studies have demonstrated the importance of CD8+ cells in the pathogenesis of IRD, but not its significance as a diagnostic tool.<sup>[11]</sup>

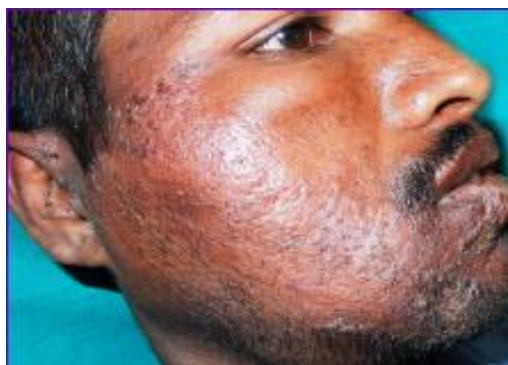Varicella-zoster when presents as IRD can cause significant morbidity in HIV-infected individuals. However, atypical or complicated cases of herpes zoster are less common in the era of HAART. In the present case, no complications occurred during the follow up period. Some studies have presented case definitions of IRD, but the lack of consensus with regard to the definition of IRD makes differentiation of IRD from recurrence or relapse of an infection a challenge. Definition of IRD is dependent on an exclusive diagnosis and on case presentations that show correlation with clinical and laboratory data.<sup>[11]</sup>

In the present case, there were clinical symptoms associated with an atypical inflammatory reaction to an opportunistic infection, this case satisfied all criteria suggested by French et al (2004) and Shelburne et al (2002).

#### IV Figures



**Fig. 1.A.** Unilateral involvement of right face. Periorbital oedema with right eye



**Fig. 1.B.** vesicular eruptions seen unilaterally on lower lip involving entire right cheek and right ear.



**Fig. 1.C.** Absence of lesion on left side of face

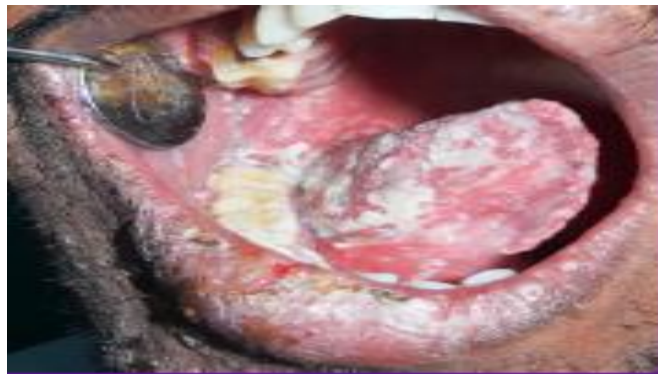
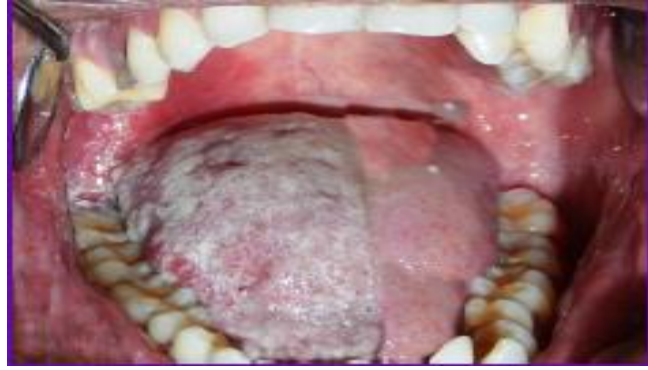
Fig. 2. A, B : White coating and erosive areas on tongue extending from tip to anterior faucial pillars and from midline to the lateral border of tongue involving ventral surface and floor of mouth .Unilateral palatal erythema

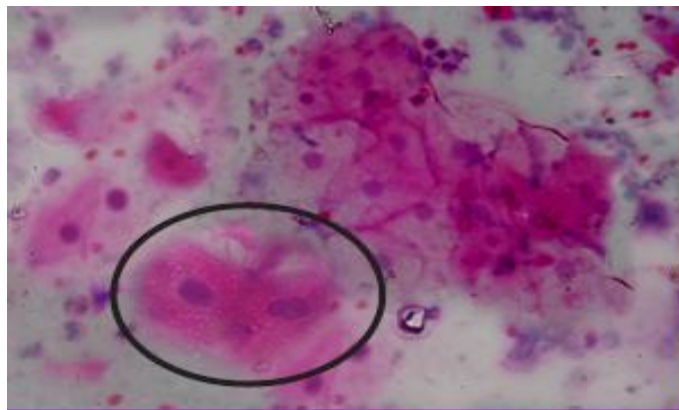
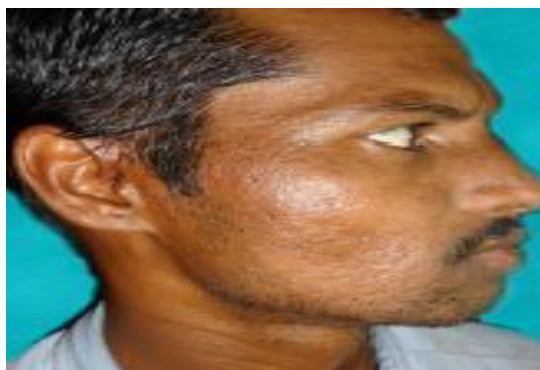
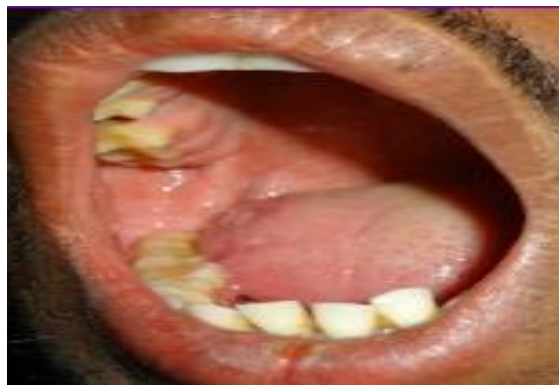
Fig. 3. Cells appear inflated with smooth external contour present in groups.





**Fig. 4. A, B :** Post-treatment follow up uneventful.

### **V Conclusion**

The importance of this disease lies in its differentiation from clinical symptoms due to failure of ART . Failure of ART includes drug resistance, toxicity, drug malabsorption, patient non - adherence to regimen. An increase in CD4 counts and decrease in viral load characterize the IRD. Decrease in CD 4 counts and increase in viral load will occur in case of failure of ART. Vaccination is not suggested .Varicella Zoster vaccines are live attenuated vaccines . They could potentially be dangerous in an immunosuppressed population.

### **References**

- [1]. Jeffrey I. Cohen. N. Herpes Zoster. *Engl J Med* 2013;369:255-63.
- [2]. Jansen K et al. Incidence and risk factors of herpes zoster among HIV-positive patients in the german competence network for HIV/AIDS (KompNet): a cohort study analysis. *BMC Infectious Diseases*. 2013; 13: 372.
- [3]. A Masiwa, S Naidoo. Oral lesions in HIV-infected patients, before and after antiretroviral treatment. *South Afr J Epidemiol Infect* 2011;26(4):271-273.
- [4]. Abdalla AO, Elkhidir IM, Bashir AA. HIV Seropositivity among Patients Presenting with Herpes Zoster Infection. *J AIDS Clin Res*. 2015; 6(1): 413.
- [5]. Blank L et al. Herpes Zoster among Persons Living with HIV in the Current ART Era. *J Acquir Immune Defic Syndr*. 2012 October 1; 61(2): 203–207.
- [6]. Martyn A. French. Immune Reconstitution Inflammatory Syndrome: A Reappraisal. *Clinical Infectious Diseases* 2009; 48:101–7.
- [7]. Domingo et al. Herpes Zoster as an Immune Reconstitution Disease after Initiation of Combination Antiretroviral Therapy in Patients with Human Immunodeficiency Virus Type-1 Infection. *American Journal of Medicine*. 2001;110:605– 609.
- [8]. Tsang, LP Samaranyake. Immune reconstitution inflammatory syndrome after highly active antiretroviral therapy: a review. *CSP Oral Diseases*. 2010; 16: 248–256.
- [9]. Liviu Feller, Neil H. Wood, Johan Lemmer. Herpes zoster infection as an immune reconstitution inflammatory syndrome in HIV-seropositive subjects: a review. *Oral Surg Oral Med Oral Pathol Oral Radiol Endod* 2007;104: 455-60.
- [10]. Jennifer C. Ranario; Claire S. Reddick; Jennifer D. Peterson; Jennifer L. Smith. Unilateral Presentation of Disseminated Candidiasis: Case Report and Review of the Literature. *Cutis* 2013; 91
- [11]. WR Choi, et al. Herpes Zoster Immune Reconstitution Inflammatory Syndrome in a HIV-infected Patient. *Infect Chemother* 2012; 44(5):391-394.